

Type 3 Multiple Autoimmune Syndrome and Vision Loss: A Case Report

MANNE LAKSHMI NARASIMHA SANDEEP¹, KARRA KEERTHI REDDY², TARUGUVANDLA SANDHYA RANI³

(CC) BY-NC-ND

ABSTRACT

Autoimmune diseases often co-exist due to shared genetic and immunological mechanisms. The term Multiple Autoimmune Syndrome (MAS) is used when three or more such diseases are present in a single patient. Early recognition of MAS is critical, as overlapping autoimmune pathologies can lead to complex, life-threatening presentations. This case describes a 25-year-old female who presented with acute, painless bilateral vision loss following a seven-day history of holocranial headache. She had recently been diagnosed with vitiligo. Examination revealed left homonymous hemianopia, and neuroimaging confirmed Cerebral Venous Thrombosis (CVT) involving the right occipito-parietal region. Laboratory investigation revealed hypothyroidism with elevated antithyroid peroxidase antibodies, consistent with Hashimoto's thyroiditis. A pro-thrombotic work-up was positive for anti-phospholipid and beta-2 glycoprotein IgM antibodies, confirmed on repeat testing after 12 weeks, establishing the diagnosis of Anti-Phospholipid Syndrome (APS). These three autoimmune diseases fulfilled the diagnostic criteria for Type 3 MAS. Although APS is not traditionally considered a component of Type 3 MAS, its co-existence with Hashimoto's thyroiditis and vitiligo in this patient warranted its inclusion. She was managed with enoxaparin followed by oral warfarin to maintain a target INR of 2.5-3.0, along with levothyroxine and atorvastatin. Her vision improved from 2/60 to 6/9 during follow-up, with no recurrence of thrombotic events. The case underscores the importance of suspecting MAS in young patients with multiple autoimmune manifestations and highlights CVT as a rare, life-threatening presentation of APS. Early diagnosis and prompt management can prevent irreversible complications. Clinicians are required to maintain a heightened level of suspicion and perform thorough autoimmune screening upon the identification of any autoimmune condition.

Keywords: Cerebral venous thrombosis, Homonymous hemianopia, Vitiligo

CASE REPORT

A 25-year-old female with a known history of vitiligo presented to the emergency department with a seven-day history of moderate, holocranial headache that had a gradual onset and worsened over time, associated with nausea. Six hours prior to admission, she reported sudden, painless diminution of vision in both eyes, without flashes, floaters, or a history of trauma or chemical exposure. There was no prior record of similar illness, no record of weakness of limbs, seizures, or speech disturbances were reported. The patient denied alcohol use, smoking, or recent use of oral contraceptive pills or abortions. Family history was unremarkable for autoimmune diseases.

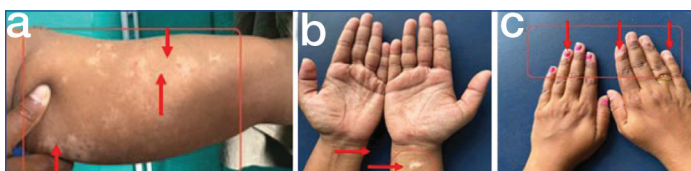
She was clinically diagnosed with vitiligo three months ago, supported by wood's lamp examination (as per Vitiligo Global Issues Consensus Conference Diagnostic Criteria for vitiligo [1]) by a dermatologist. For this, she was using topical corticosteroid cream (fluticasone 0.1%) for local application and undergoing Narrow-Band Ultraviolet B (NB-UVB) phototherapy twice a week.

Patient was conscious and oriented to time, place, and person, with a thin built and stable vital signs. The thyroid was enlarged and palpable bilaterally, with no tenderness. The skin showed multiple ill-defined, chalky white hypopigmented patches over bilateral palms [Table/Fig-1a] and arms [Table/Fig-1b,c], consistent with vitiligo, with no signs of inflammation or scarring.

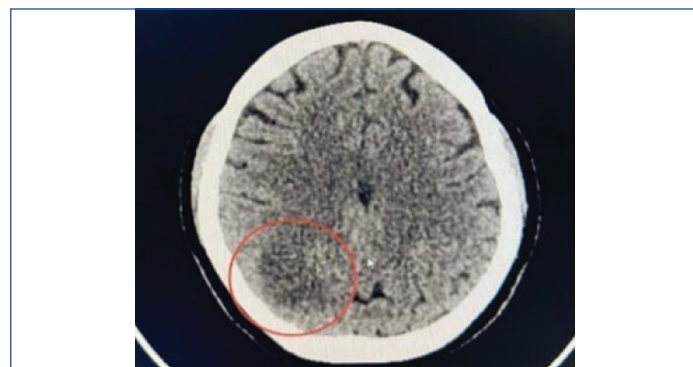
Head and neurological assessment revealed abnormalities in cranial nerve II, with reduced visual acuity of 2/60 in both eyes and left

homonymous hemianopia on confrontation visual field testing. The fundus was normal, with no papilloedema, retinal haemorrhages, or vascular abnormalities. No other cranial nerve abnormalities were noted. Motor examination revealed normal muscle tone, power, and deep tendon reflexes. The sensory examination was unremarkable, with intact touch, pain, and vibration sense. Cerebellar function testing was normal, with no dysmetria or ataxia.

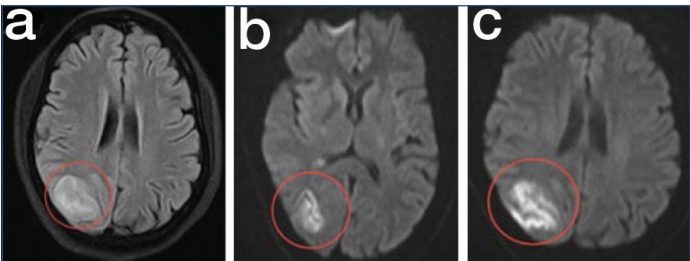
Given the normal eye examination and suspicion of a retro-orbital cause for the visual defect, neuroimaging was pursued, which later correlated with the Cerebral Venous Thrombosis (CVT) affecting optic radiations. A Computed Tomography (CT) brain scan revealed an acute infarct in the right occipito-parietal region, with punctate foci of haemorrhage and thrombosed cortical vein [Table/Fig-2]. Magnetic Resonance Imaging (MRI) of the brain revealed a hyperintense lesion in the right occipital region on Fluid-Attenuated Inversion Recovery (FLAIR) [Table/Fig-3a] and restricted diffusion on Diffusion Weighted Imaging (DWI) [Table/Fig-3b,c], consistent with acute infarction. MR venography confirmed a thrombosis of right transverse sinus [Table/Fig-4], supporting the diagnosis of CVT, which causing left homonymous hemianopia.



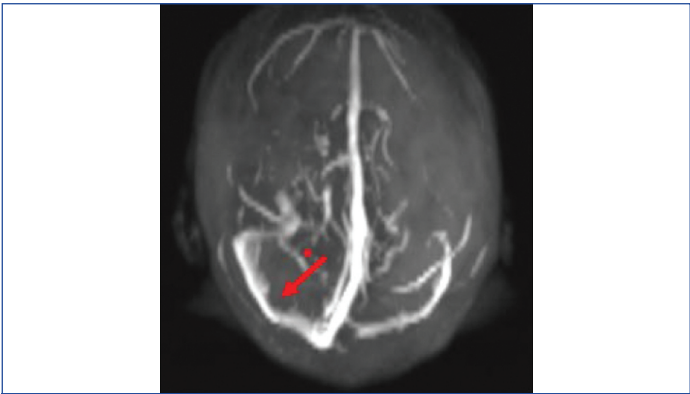
[Table/Fig-1]: Multiple ill-defined hypopigmented chalky patches on bilateral palms and arms indicative of vitiligo.



[Table/Fig-2]: Brain CT image – Showing hypodensity in the right occipito-parietal region with a red oval highlighting an acute infarct.



[Table/Fig-3]: a) FLAIR image showing a hyperintense lesion in the right occipital region, suggestive of an infarct with surrounding oedema; b&c) Diffusion-weighted images displaying a hyperintense area in the occipital region, indicating an acute infarct.

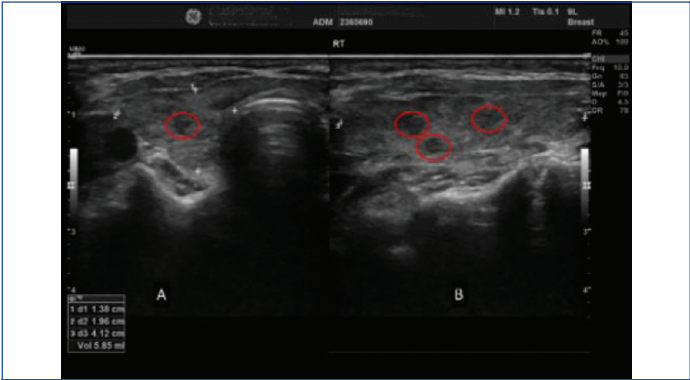


[Table/Fig-4]: MRI venogram: venous filling defect in the right transverse sinus, indicating thrombosis.

The thyroid function test revealed low free T4 (0.4 ng/dL, normal 0.58-1.64 ng/dL), elevated TSH (12.83 μ IU/mL, normal 0.4-4.0 μ IU/mL), and raised antithyroid peroxidase antibodies (9.2 IU/mL, normal \leq 5.61 IU/mL) [Table/Fig-5], meeting American Thyroid Association criteria for Hashimoto's thyroiditis [2], supported by a heterogeneous thyroid with hypoechoic areas on ultrasound [Table/Fig-6]. These results prompted a broader autoimmune evaluation. Pro-thrombotic work-up identified elevated anti-phospholipid IgM (17.3) and beta-2 glycoprotein IgM (3.14), confirmed after 12 weeks (IgM 16.2, beta-2 glycoprotein IgM 2.95), satisfying the revised Sapporo criteria for a diagnosis of APS [Table/Fig-7a,b] [3].

Parameter	Results	Normal range
Free T3 (pg/mL)	3.65	2.5-3.9 pg/mL
Free T4 (ng/dL)	0.4	0.58-1.64 ng/dL
TSH (μ IU/mL)	12.83	0.4-4.0 μ IU/mL
Anti-TPO (IU/mL)	9.2	\leq 5.61 IU/mL

[Table/Fig-5]: Thyroid function test results [2].
Anti-TPO: Thyroid peroxidase; TSH: Thyroid stimulating hormone



[Table/Fig-6]: Ultrasound neck revealing a heterogeneous thyroid with hypoechoic areas consistent with Hashimoto's thyroiditis.

Given the combination of vitiligo, Hashimoto's thyroiditis, and APS, a connective tissue disease was suspected. However, extended autoimmune testing-including antinuclear antibody and extractable nuclear antigen panels (anti-Jo-1, anti-Smith, anti-SS-A/Ro, anti-SS-B/La, anti-RNP/Sm, anti-CENP B, anti-dsDNA, anti-histones,

Coagulation profile	Initial results	Reference value
Lupus Anticoagulant	Not detected -	
Anti-Cardiolipin igG	Negative (0.13)	Negative: <1.0 Positive: \geq 1.0
Anti-Cardiolipin igM	Negative (0.76)	
Anti-Phospholipid IgG	Normal (3.9)	Normal: <10.0 Elevated: \geq 10.0
Anti-Phospholipid IgM	Elevated (17.3)	
Beta 2 Glycoprotein-1 (IgM)	Positive (3.14)	Negative: <1.0 Positive: \geq 1.0
Beta 2 Glycoprotein-1 (IgG)	Negative (0.10)	
Anti-Thrombin III	92.4%	70-121% 3.7-13.9
Serum Homocysteine	6.9	

[Table/Fig-7a]: Coagulation profile- initial results [3].

Coagulation profile	Results after 12 weeks	Reference value
Lupus Anticoagulant	Not detected -	
Anti-Cardiolipin igG	Negative (0.58)	Negative: <1.0 Positive: \geq 1.0
Anti-Cardiolipin igM	Negative (0.40)	
Anti-Phospholipid IgG	Normal (4.8)	Normal: <10.0 Elevated: \geq 10.0
Anti-Phospholipid IgM	Elevated (16.2)	
Beta 2 Glycoprotein-1 (IgM)	Positive (2.95)	Negative: <1.0 Positive: \geq 1.0
Beta 2 Glycoprotein-1 (IgG)	Negative (0.12)	

[Table/Fig-7b]: Coagulation profile- after 12 weeks [3].

anti-nucleosomes, anti-PM-Scl, anti-PCNA, anti-DFS70) and anti-mitochondrial antibodies-was negative [Table/Fig-8] [4], effectively ruling out systemic lupus erythematosus, Sjögren's syndrome, and other connective tissue disorders.

ENA profile	Results
Antinuclear antibody test	Negative
Antibody to JO-1	Negative
Antibody to Scl70	Negative
Antibody to Sm (Smith)	Negative
Antibody to SS-A (RO)	Negative
Antibody to SS-B (LA)	Negative
Antibody to Rib.Po	Negative
Antibody to U1-nRNP/Sm [#]	Negative
Antibody to CENP B	Negative
Antibody to dsDNA	Negative
Antibody to histones	Negative
Antibody to nucleosomes	Negative
Antibody to PM-Scl	Negative
Antibody to Ro-52	Negative
Antibody to PCNA	Negative
Antibody mitochondrial antibody	Negative
Antibody to DFS70	Negative

[Table/Fig-8]: Extractable nuclear antigens [4].

The patient was initiated on anticoagulation with enoxaparin (1 mg/kg subcutaneously twice daily) for acute CVT and was later transitioned to an oral vitamin K antagonist (warfarin 2 mg), adjusted to maintain an INR of 2.5-3.0. Atorvastatin (20 mg) was added to mitigate cardiovascular risk and prevent further thrombosis. Levothyroxine (75 mcg) was to treat her hypothyroidism by Hashimoto's thyroiditis.

To address potential cerebral oedema and seizure risk due to punctate haemorrhage, mannitol (100 mL of 20% solution every 6 hours) and levetiracetam (1,000 mg i.v. loading dose, followed by 500 mg twice daily for 5 days) were administered. These medications were discontinued upon clinical improvement and absence of seizures or significant oedema. The patient was closely monitored for neurological deterioration, and serum osmolality and renal function test were assessed during mannitol use.

Her visual acuity improved from 2/60 to 6/9, likely due to resolution of cerebral oedema and reperfusion of the optic radiations following anticoagulation. Long-term follow-up includes monthly INR monitoring, thyroid function tests every six weeks, and semi-annual neurological and ophthalmological evaluations to detect recurrence or new autoimmune manifestations. With adherence to therapy, the prognosis is favourable, although there remains a 10-20% risk of recurrent thrombosis, necessitates lifelong vigilance.

DISCUSSION

The MAS, initially described by Humbert and Dupond in 1988 [5], denotes the presence of three or more autoimmune conditions in one individual, with about 25% of those with an autoimmune disorder developing additional ones [6]. Type 3 MAS encompasses diseases such as vitiligo, autoimmune thyroid disease, and others, though APS is not traditionally included [7]. This case presents a unique triad of vitiligo, Hashimoto's thyroiditis, and APS, validated by their co-existence and APS's contribution to CVT. The patient's young age and simultaneous onset of these conditions highlight the necessity of considering MAS in young adults with unexplained systemic symptoms [8].

CVT, a rare manifestation of APS, presented with headache (88.9% prevalence) and focal deficits (29.6%), including hemianopia in this patient [9]. Genetic predispositions, including HLA-DR3/DR4 alleles and polymorphisms in PTPN22 and FOXP3, alongside immune dysregulation with elevated cytokines {Interferon-Gamma (IFN- γ), Tumour Necrosis Factor-Alpha (TNF- α), Interleukin (IL)-2} and autoreactive T/B cells, are implicated [10]. At the core, all three conditions involve a loss of immune tolerance to self-antigens, allowing autoreactive immune cells to escape deletion or inactivation. This breakdown of tolerance and the resulting immune dysregulation form a common pathogenic thread linking these otherwise clinically distinct autoimmune diseases [11].

The rapid onset contrasts with the typical multi-year latency (mean 11.3 years) reported in autoimmune polyglandular syndromes [7], suggesting a need for early screening in genetically susceptible individuals [8]. Comparative cases, such as APS with thyroiditis [12] or Hashimoto's with vitiligo [13], are documented, but this triad's simultaneity is exceptional, potentially aligning with autoimmune polyglandular syndrome type III variants [14].

Treatment effectively reversed vision loss, demonstrating the value of anticoagulation, thyroid replacement, and supportive care. The absence of genetic testing limits insight into predisposition, while the lack of functional imaging or visual evoked potentials hinders precise visual pathway assessment. Environmental or infectious triggers, which might have precipitated this clustering, were not explored. These gaps suggest areas for future investigation. Clinicians should prioritise comprehensive autoimmune screening, including repeat Antiphospholipid Antibody (APLA) testing after 12 weeks and neuroimaging for neurological symptoms, to mitigate severe outcomes. This case reinforces the importance of early detection and tailored management in MAS, enhancing research and follow-up strategies for affected patients [15].

Thus, this case shows that APS can present with CVT and vision loss; timely imaging and anticoagulation are lifesaving. Dermatological and thyroid manifestations may precede severe neurological events. Screening for autoimmune clusters is crucial in young patients with systemic symptoms.

CONCLUSION(S)

This case illustrates a rare presentation of type 3 MAS, comprising vitiligo, Hashimoto's thyroiditis, and APS, with acute vision loss due to CVT. While APS is not traditionally part of type 3 MAS, its co-existence in this young patient underscores the need to revise classical groupings based on evolving clinical evidence. Early diagnosis through comprehensive autoimmune work-up and prompt management significantly improved the patient's neurological outcome. Clinicians should maintain a high index of suspicion for MAS in patients with multiple autoimmune conditions and unusual systemic symptoms, as early intervention can prevent potentially fatal complications.

REFERENCES

- [1] Taieb A, Picardo M, other VETF members. The definition and assessment of vitiligo: A consensus report of the Vitiligo European Task Force. *Pigment Cell Melanoma Res.* 2007;20(1):27-35.
- [2] Garber JR, Cobin RH, Gharib H, Hennessey JV, Klein I, Mechanick JL, et al. Clinical practice guidelines for hypothyroidism in adults: Cosponsored by the American Association of Clinical Endocrinologists and the American Thyroid Association. *Endocr Pract.* 2012;18(6):988-1028.
- [3] Miyakis S, Lockshin MD, Atsumi T, Branch DW, Cervera RH, et al. International consensus statement on an update of the classification criteria for definite antiphospholipid syndrome (APS). *J Thromb Haemost.* 2006;4(2):295-306.
- [4] Fritzler MJ. Advances and applications of multiplexed diagnostic technologies in autoimmune diseases. *Lupus.* 2006;15(7):422-27.
- [5] Humbert P, Dupond JL. Les syndromes auto-immuns multiples (S.A.M.) [Multiple autoimmune syndromes]. *Ann Med Interne (Paris).* 1988;139(3):159-68. French. PMID: 3059902.
- [6] Cojocaru M, Cojocaru IM, Silosi I. Multiple autoimmune syndrome. *Maedica (Buchar).* 2010;5(2):132-34.
- [7] Boccuti V, Perrone A, D'Introno A, Campobasso A, Sangineto M, Sabba C. An unusual association of three autoimmune disorders: Celiac disease, systemic lupus erythematosus and Hashimoto's thyroiditis. *Autoimmun. Highlights.* 2016;7:01-03.
- [8] Topal F, Senel E, Akbulut S, Topal F, Dölek Y. A new combination of multiple autoimmune syndrome? Coexistence of vitiligo, autoimmune thyroid disease and ulcerative colitis. *Dermatol Reports.* 2011;3(2):e19.
- [9] Jerez-Lienas A, Mathian A, Aboab J, Crassard I, Hie M, Cohen-Aubart F, et al. Cerebral vein thrombosis in the antiphospholipid syndrome: Analysis of a series of 27 patients and review of the literature. *Brain Sci.* 2021;11(12):1641.
- [10] Sarfaraz S, Anis S. Multiple autoimmune syndrome: An unusual combination of autoimmune disorders. *Rev Recent Clin Trials.* 2020;15(3):240-43.
- [11] Sun W, Zhu C, Li Y, Wu X, Shi X, Liu W. B cell activation and autoantibody production in autoimmune diseases. *Best Pract Res Clin Rheumatol.* 2024;38(2):101936.
- [12] Jain A. Antiphospholipid antibody syndrome associated with graves' disease presenting as inferior vena cava thrombosis with bilateral lower limb DVT. *Clin Med Insights Case Rep.* 2014;7:37-39. Doi: 10.4137/CCRep.S15302. PMID: 24812529; PMCID: PMC3999708.
- [13] Sun Y, Kan X, Zheng R, Hao L, Mao Z, Jia Y. Hashimoto's thyroiditis, vitiligo, anemia, pituitary hyperplasia, and lupus nephritis—A case report of autoimmune polyglandular syndrome type III C+ D and literature review. *Front Pediatr.* 2023;11:1062505.
- [14] Townley RG. Clinical reviews in allergy and immunology: Preface. *Clin Rev Allergy Immunol.* 2003;24(1):01-05.
- [15] Richard-Miceli C, Criswell LA. Emerging patterns of genetic overlap across autoimmune disorders. *Genome Med.* 2012;4:01-09.

PARTICULARS OF CONTRIBUTORS:

1. Third Year Junior Resident, Department of General Medicine, SRM Medical College Hospital and Research Centre, Chennai, Tamil Nadu, India.
2. Third Year Junior Resident, Department of General Medicine, SRM Medical College Hospital and Research Centre, Chennai, Tamil Nadu, India.
3. Third Year Junior Resident, Department of General Medicine, SRM Medical College Hospital and Research Centre, Chennai, Tamil Nadu, India.

NAME, ADDRESS, E-MAIL ID OF THE CORRESPONDING AUTHOR:

Dr. Taruguvandla Sandhya Rani,
Room No. A62, B.C. Roy Hostel, SRM Medical College Hospital and Research
Centre, Kattankulathur, Chennai-603203, Tamil Nadu, India.
E-mail: tsandy198@gmail.com

AUTHOR DECLARATION:

- Financial or Other Competing Interests: None
- Was informed consent obtained from the subjects involved in the study? Yes
- For any images presented appropriate consent has been obtained from the subjects. Yes

PLAGIARISM CHECKING METHODS: [Jain H et al.]

- Plagiarism X-checker: Mar 27, 2025
- Manual Googling: May 29, 2025
- iThenticate Software: Jun 21, 2025 (6%)

ETYMOLOGY: Author Origin

EMENDATIONS: 6

Date of Submission: **Mar 09, 2025**

Date of Peer Review: **May 01, 2025**

Date of Acceptance: **Jun 23, 2025**

Date of Publishing: **Aug 01, 2025**